

AXIAL SPONDYLOARTHRITIS: PATHOGENESIS, CLINICAL PRESENTATION, AND DISEASE BURDEN



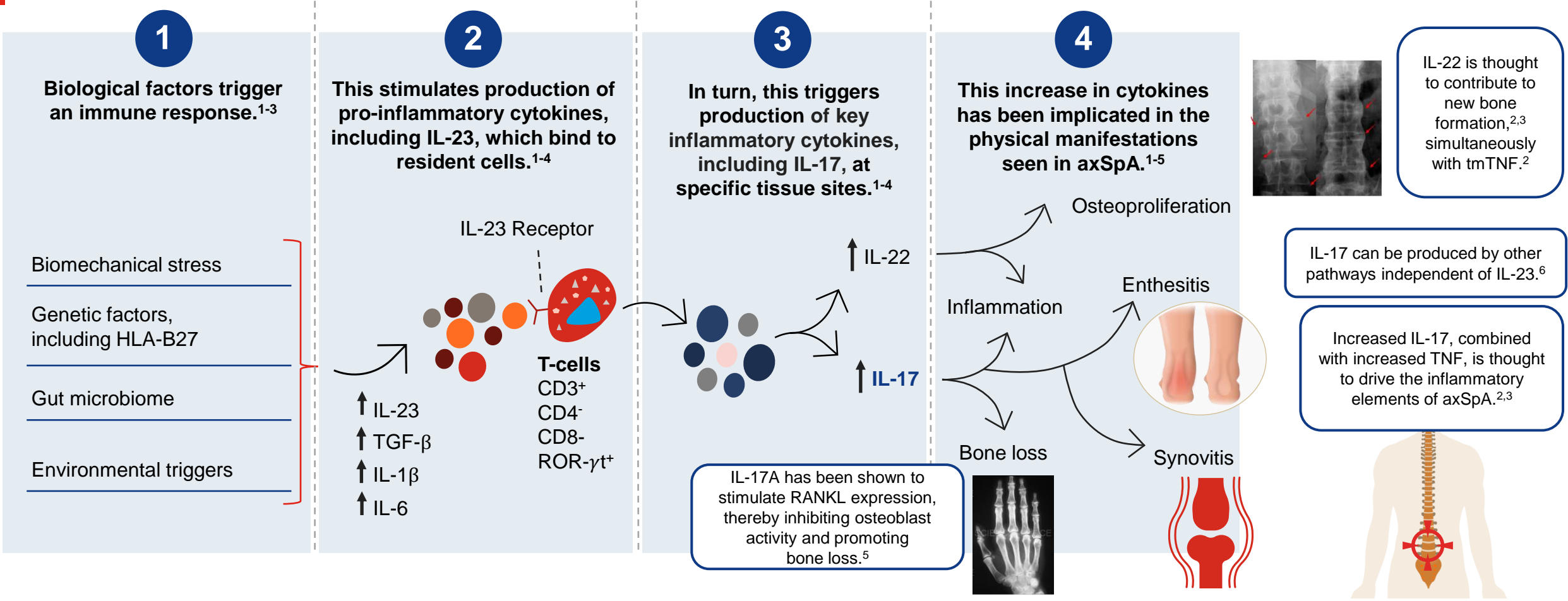
Learning Objectives



- Describe the pathophysiology of AS/r-axSpA and nr-axSpA, and role of HLA-B27 in the pathogenesis of axSpA
- Describe the axSpA disease spectrum, natural history, and differentiate AS/r-axSpA and nr-axSpA
- Describe the clinical presentation of AS/r-axSpA vs. nr-axSpA, symptoms, manifestations, and similarities and differences
- Explain how axSpA carries a high disease burden
- Explain the relationship between the delay in diagnosing axSpA and high patient burden

Pathophysiology of AS/r-axSpA and nr-axSpA

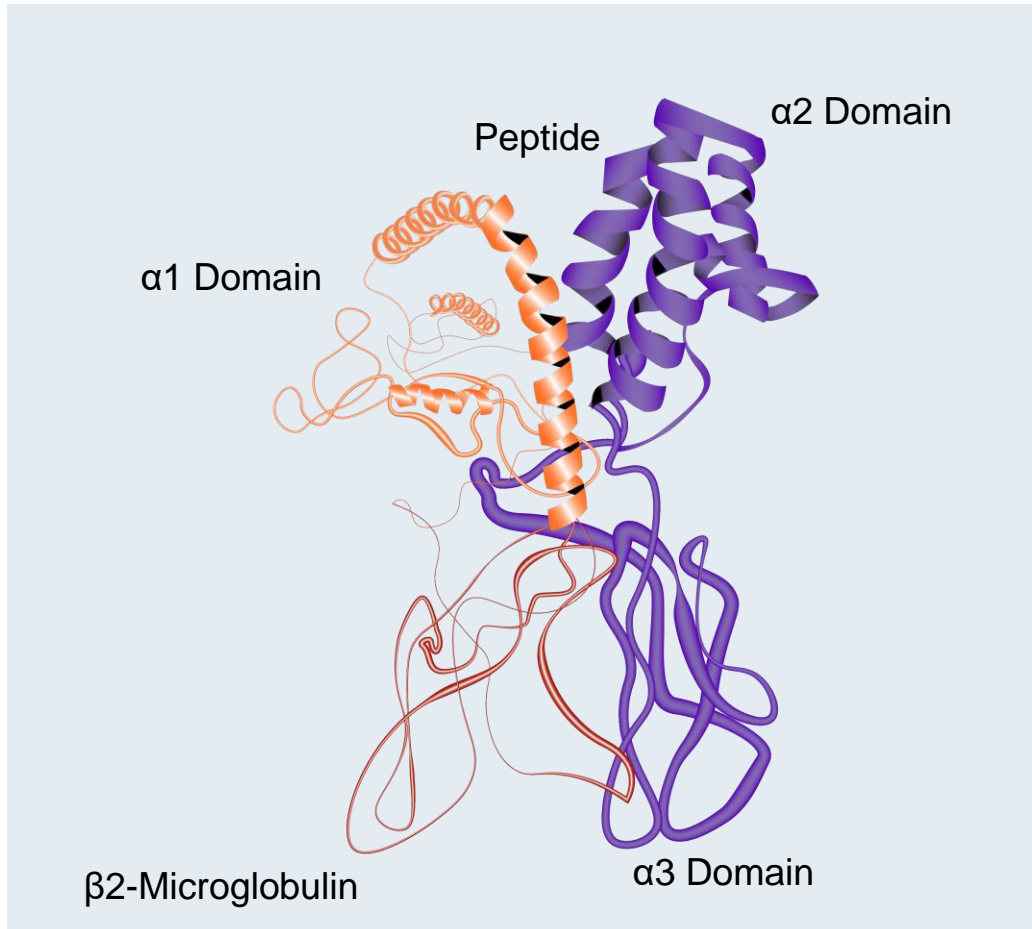
The IL-23/IL-17 Pathway is Key in axSpA Pathogenesis



Osteoproliferation image: Image is licensed under CC BY 4.0. Permission has been obtained for reuse. Available at: <https://journals.plos.org/plosone/article?id=10.1371/journal.pone.0204546> (Accessed May 2, 2023).
 axSpA=Axial Spondyloarthritis; CD=Cluster of Differentiation; HLA-B27=Human Leukocyte Antigen-B27; IL=Interleukin; RANKL=Receptor Activator of Nuclear Factor- κ B Ligand; ROR- γ t=Retinoid-Related Orphan Receptor Gamma t; sTNF= Soluble Tumor Necrosis Factor; tmTNF=Transmembrane Tumor Necrosis Factor; TGF- β =Transforming Growth Factor- β .
 1. Paine A, Ritchlin CT. *Curr Opin Rheumatol*. 2016;28(4):359-367. 2. Sieper J, et al. *Nat Rev Dis Primers*. 2015;1:15013. 3. Taurog JD, et al. *N Engl J Med*. 2016;374(26):2563-2574. 4. Lories RJ, McInnes IB. *Nat Med*. 2012;18(7):1018-1019. 5. McGonagle DG, et al. *Ann Rheum Dis*. 2019;78(9):1167-1178. 6. Navarro-Compán V, et al. *Front Immunol*. 2023;14:1191782.

The Role of HLA-B27 in axSpA

3D Structure of HLA-B27¹



Prevalence of HLA-B27



<10%

In the general population²⁻⁴



70%-90%

In White patients with
axSpA^{2,4,5}

axSpA=Axial Spondyloarthritis; HLA=Human Leukocyte Antigen; RCSB=Research Collaboratory for Structural Bioinformatics.

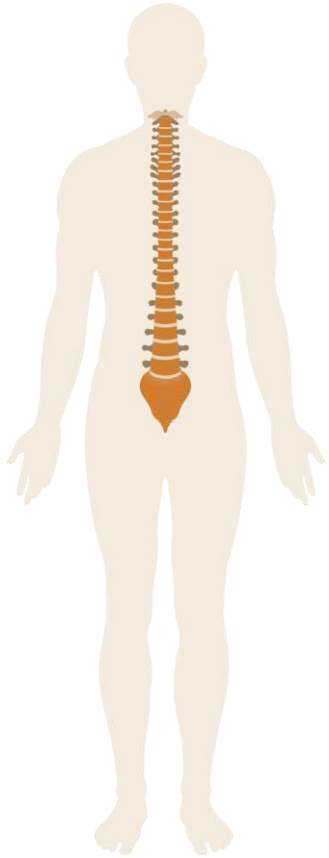
1. López-Larrea C, et al. *Mol Med Today*. 1998;4(12):540-549. 2. Walsh JA, Magrey M. *J Clin Rheumatol*. 2021;27(8):e547-e560. 3. Reveille JD, et al. *Arthritis Rheumatol*. 2012;64(5):1407-1411.

4. Sieper J, et al. *Nat Rev Dis Primers*. 2015;1:15013. 5. Taurog JD, et al. *N Engl J Med*. 2016;374(26):2563-2574.

axSpA Disease Overview

axSpA Disease Spectrum

Axial spondyloarthritis (axSpA) refers to the inflammation of the axial skeleton and encompasses two subtypes of the same disease: **AS/r-axSpA** and **nr-axSpA**.^{1,2}



axSpA

- A chronic inflammatory disease of the sacroiliac joint and the axial skeleton.
- May involve peripheral or other joints and entheses.
- May also involve extra-musculoskeletal manifestations including intestines, skin, eyes, lung, and heart.^{3,4}

AS/r-axSpA versus nr-axSpA

AS/r-axSpA

Presence of radiographic changes of the sacroiliac joints consistent with sacroiliitis (as defined by the modified New York criteria).^{1,5}

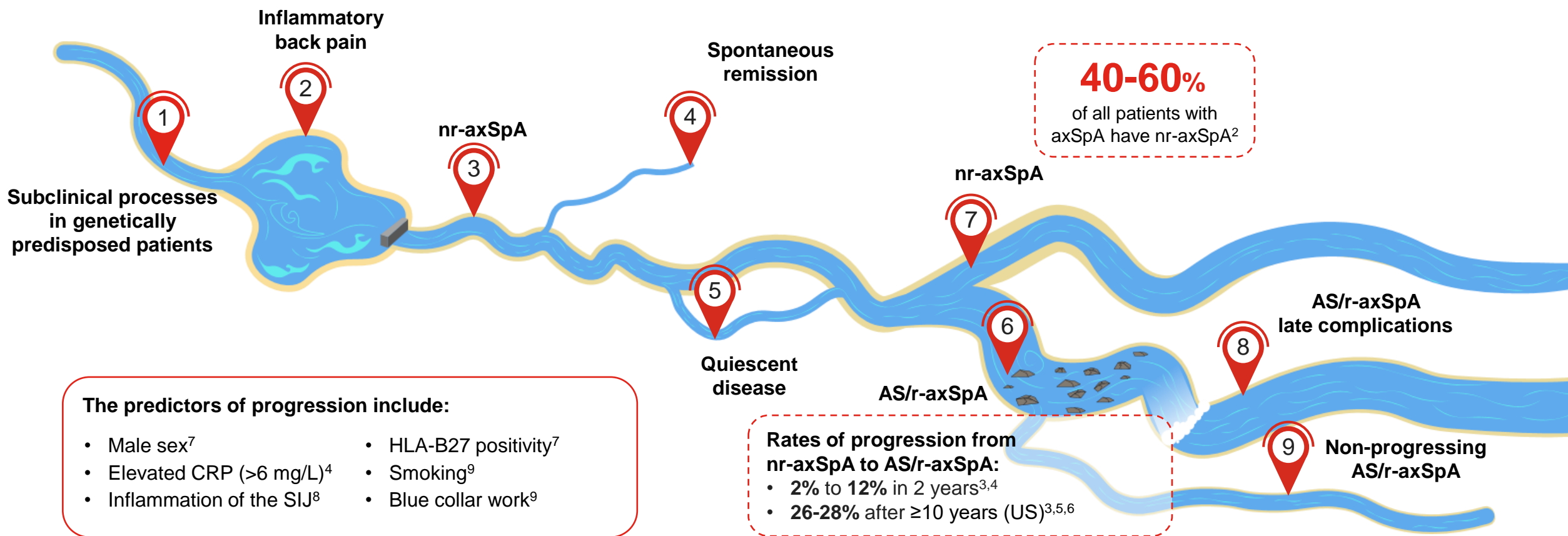
nr-axSpA

Absence of radiographic changes of the sacroiliac joints consistent with sacroiliitis (as defined by the modified New York criteria).^{1,5}

AS=Ankylosing Spondylitis; axSpA=Axial Spondyloarthritis; nr-axSpA=Nonradiographic Axial Spondyloarthritis; r-axSpA=Radiographic Axial Spondyloarthritis.

1. Taurog JD, et al. *N Engl J Med*. 2016;374:2563-2574. 2. Proft F, Poddubnyy D. *Ther Adv Musculoskel Dis*. 2018;10(5-6):129-139. 3. van der Heijde D. Ankylosing Spondylitis. In: *Primer on the Rheumatic Diseases*, Klippel JH, Stone JH, Crofford LJ, White PH (eds). Springer New York. 2008. 4. Navarro-Compán V, et al. *Ann Rheum Dis*. 2021;80(12):1511-1521. 5. van der Linden S, et al. *Arthritis Rheum*.1984;27:361-368.

Natural History of axSpA¹



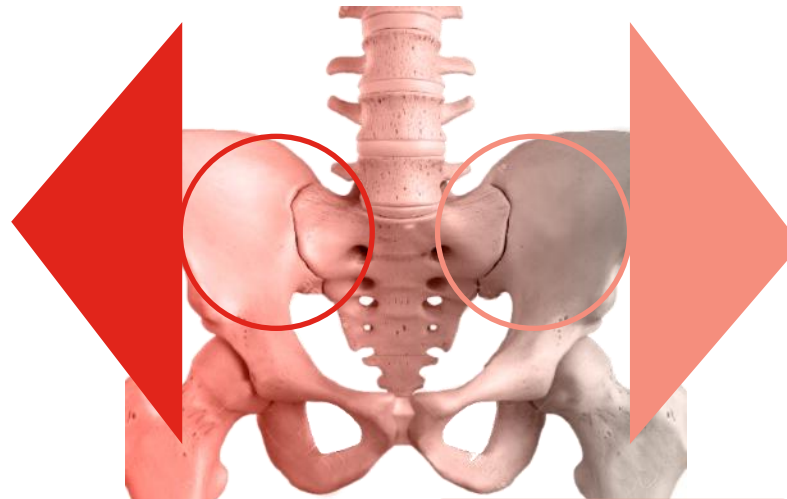
AS=Ankylosing Spondylitis; axSpA=Axial Spondyloarthritis; CRP=C-Reactive Protein; HLA-B27=Human Leukocyte Antigen B27; nr-axSpA=Nonradiographic Axial Spondyloarthritis; r-axSpA=Radiographic Axial Spondyloarthritis; SIJ=Sacroiliac Joint; US=United States.

1. Garg N, et al. *Best Pract Res Clin Rheumatol*. 2014;28:663-672. 2. Deodhar A, et al. *Lancet*. 2020;395:53-64. 3. Ruderman E, et al. *Arthritis Rheum*. 2013;65:S1052-1053. 4. Poddubny D, et al. *Ann Rheum Dis*. 2011;70(8):1369-1374. 5. Ghosh N, Ruderman EM. *Arthritis Res Ther*. 2017;19(1):286. 6. Wang R, et al. *Arthritis Rheumatol*. 2016;68(6):1415-1421 7. Poddubny D, et al. *Ann Rheum Dis*. 2022;81:96-97. Abstract OP0149. 8. Molto A, et al. *Ann. Rheum. Dis*. 2024;83(7):858-864. 9. Nikiphorou E, et al. *Arthritis Rheumatol*. 2020;72(11):1855-1862.

Differentiating AS/Radiographic axSpA and Nonradiographic axSpA

Inflammation of the axial skeleton on MRI

Structural SI joint damage^{2-4*}



Inflammation of the axial skeleton on MRI

Without structural SI joint damage^{2-4*}

AS/r-axSpA

nr-axSpA

Clinical features do not differ^{1,2,5}

Pain

Enthesitis

Functional impairment

Elevated CRP

SpA features

***Given the subjective interpretation of the SI joint via x-ray,
the distinction between AS/r-axSpA and nr-axSpA is not absolute.¹***

*According to modified New York criteria.³

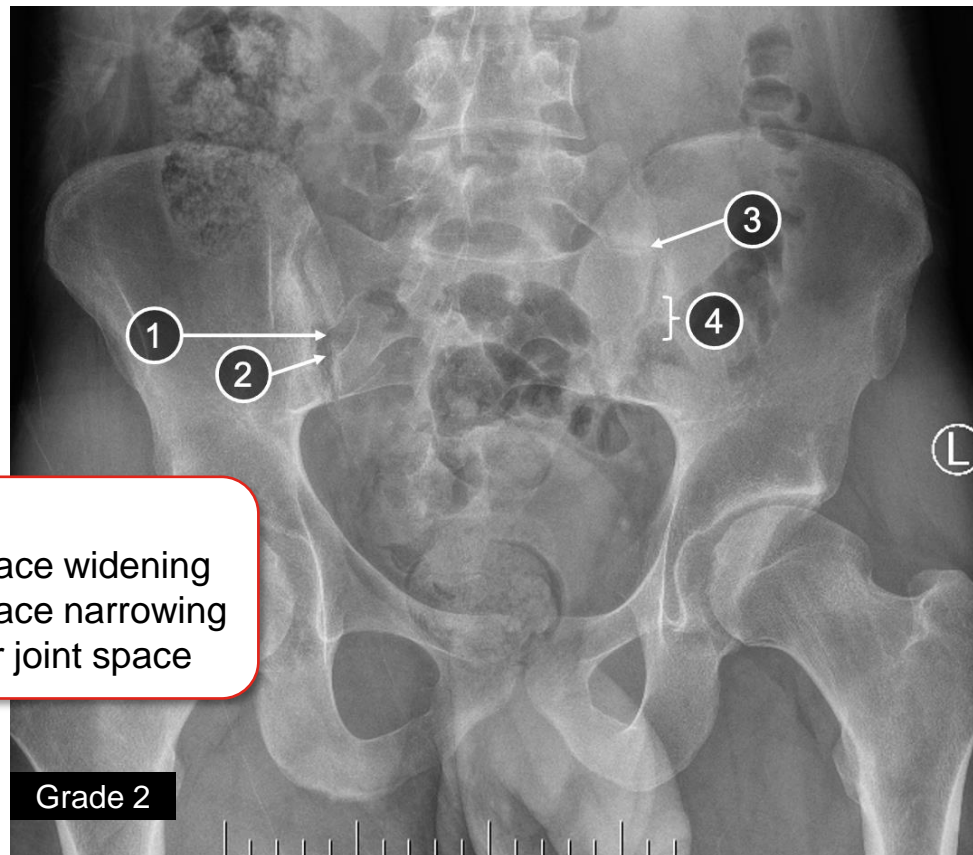
AS=Ankylosing Spondylitis; axSpA=Axial Spondyloarthritis; nr-axSpA=Nonradiographic Axial Spondyloarthritis; r-axSpA=Radiographic Axial Spondyloarthritis; SI=Sacroiliac.

1. Deodhar AA. *Am J Managed Care*. 2019;25(17, suppl):S319-S330. 2. Baraliakos X, et al. *RMD Open*. 2015;1:e000053. 3. van der Linden S, et al. *Arthritis Rheum*.1984;27:361-368. 4. Mease PJ, et al. *Arthritis Care Res*. 2018;70(11):1661-1670. 5. Sieper J, et al. *Ann Rheum Dis*. 2009;68 Suppl 2:ii1-44 [page ii23 (Figure 29) and ii6 (Box 10C)].

SIJ Skeletal Changes in Early Versus Late Stage AS/r-axSpA

Radiograph

Early

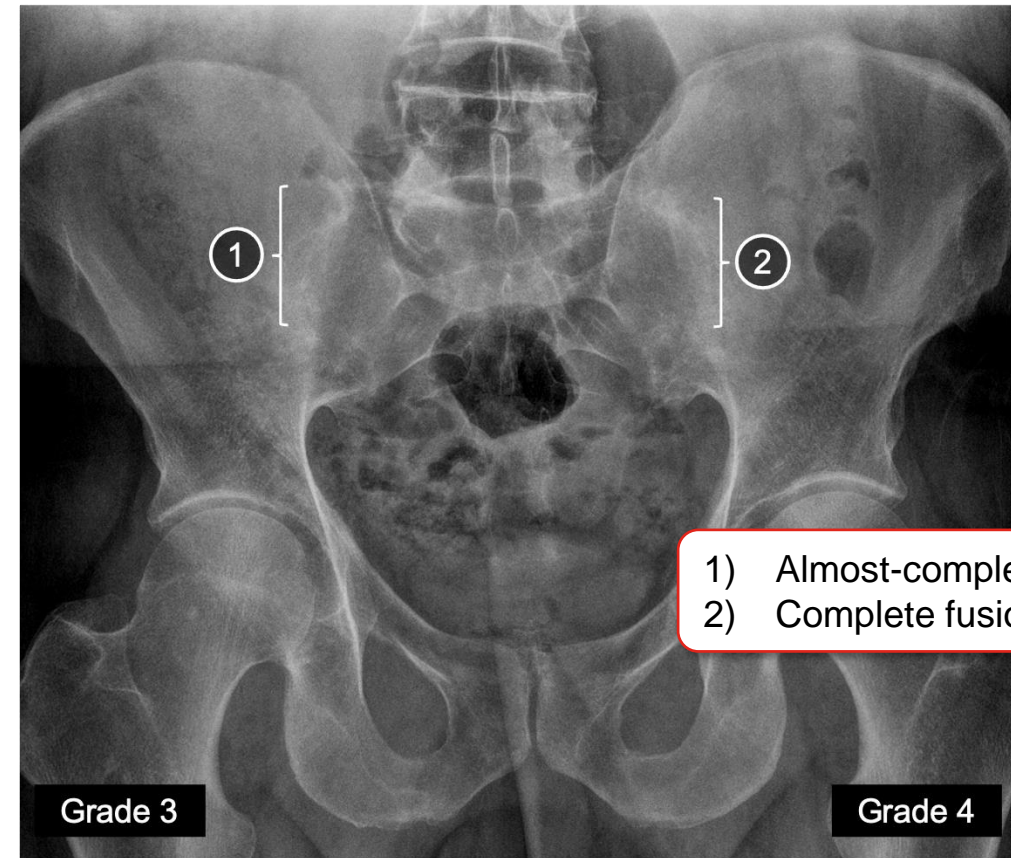


- 1) Erosion
- 2) Joint space widening
- 3) Joint space narrowing
- 4) Irregular joint space

Grade 2

SIJ Skeletal Changes in early stage AS/r-axSpA: Image courtesy of Dr. R. Inman

Late



- 1) Almost-complete fusion
- 2) Complete fusion

Grade 3

Grade 4

SIJ Skeletal Changes in late stage AS/r-axSpA: Image courtesy of Dr. R. Inman

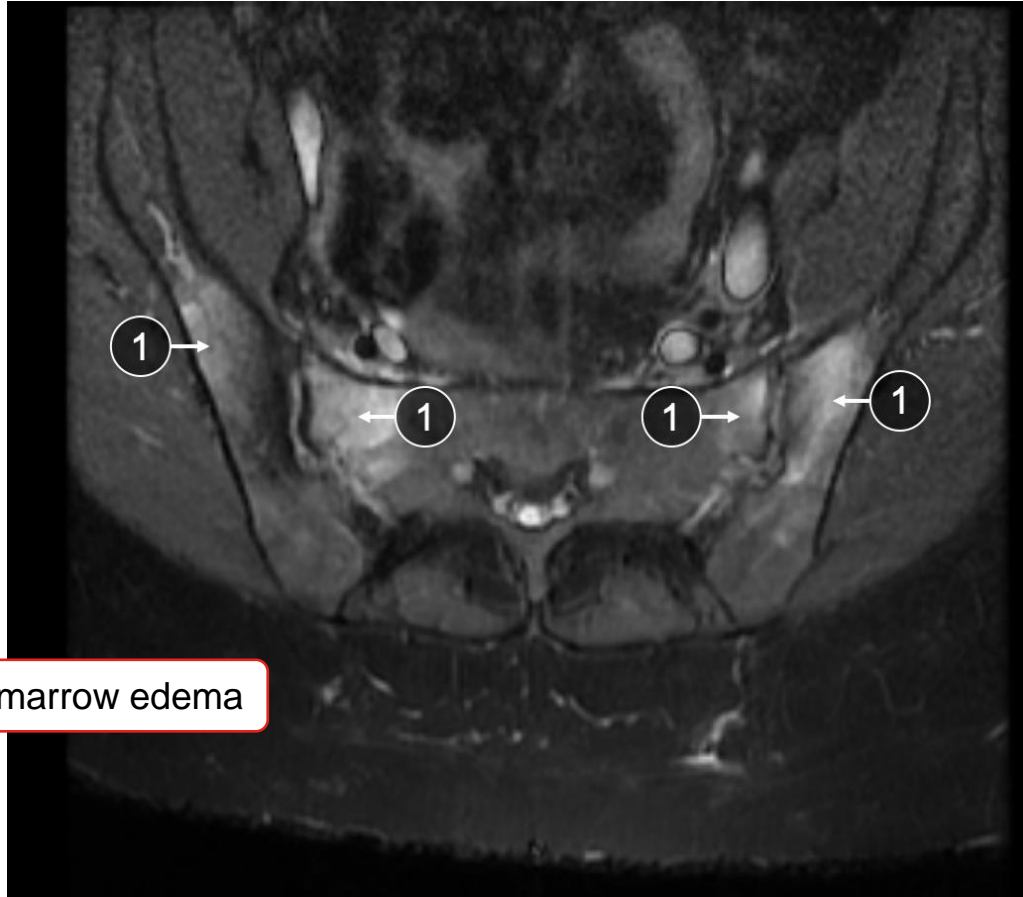
AS=Ankylosing Spondylitis; r-axSpA=Radiographic Axial Spondyloarthritis; SIJ=Sacroiliac Joint.

Lilly AS/r-axSpA nr-axSpA 3D Explorer. <https://medical.lilly.com/us/diseases/disease-education-resources/rheumatology/axial-spondyloarthritis/education-resources/axial-spondyloarthritis-as-nr-axspa-3d-explorer-as-r-axspa> (Accessed January 30, 2025).

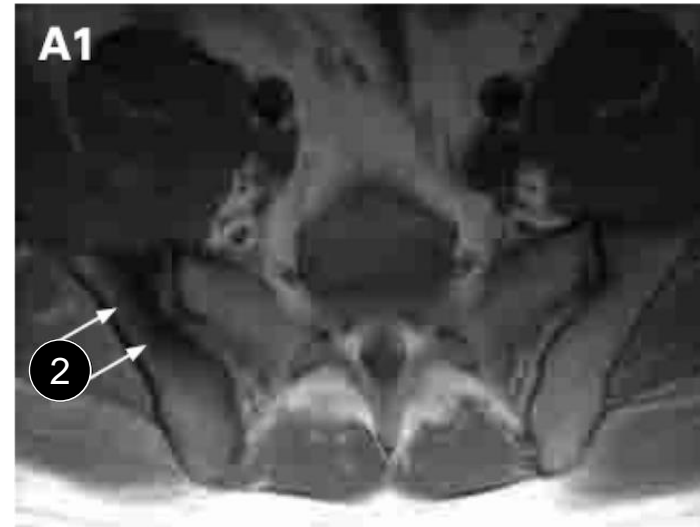
SIJ Inflammation Changes in Early Versus Late Stage AS/r-axSpA

MRI

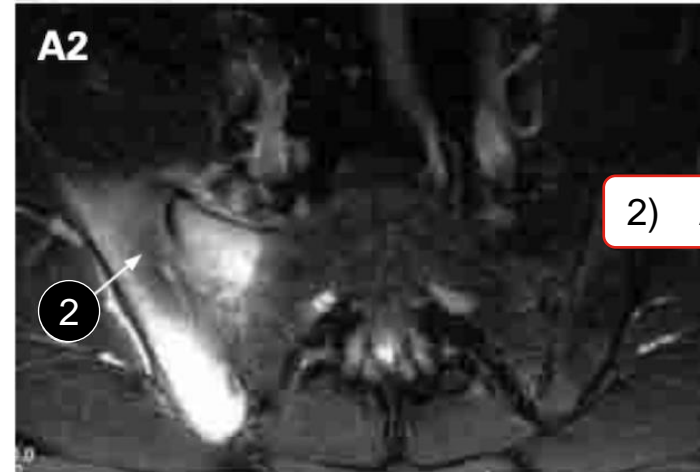Early¹



1) Bone marrow edema



Late²



2) Area of sclerosis

SIJ Inflammation Changes in early stage AS/r-axSpA: Image courtesy of Dr. R. Inman

AS=Ankylosing Spondylitis; MRI=Magnetic Resonance Imaging; r-axSpA=Radiographic Axial Spondyloarthritis; SIJ=Sacroiliac Joint.

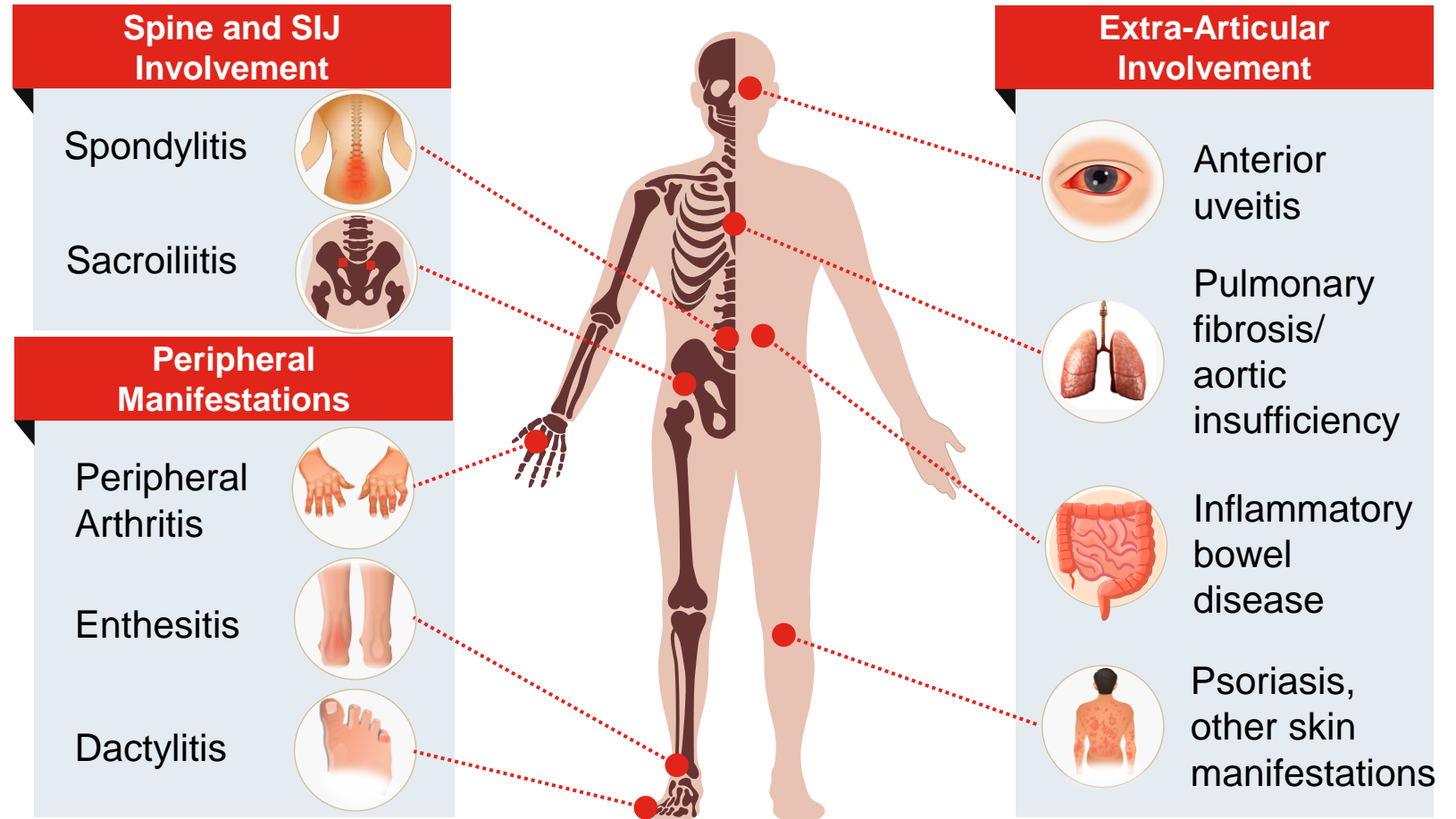
1. Lilly AS/r-axSpA nr-axSpA 3D Explorer: <https://medical.lilly.com/us/diseases/disease-education-resources/rheumatology/axial-spondyloarthritis/education-resources/axial-spondyloarthritis-as-nr-axspa-3d-explorer-as-r-axspa> (Accessed January 30, 2025). 2. Sieper J, et al. *Ann Rheum Dis*. 2009;68 Suppl 2:ii1-44 [page ii11, Box 17, A1 and A2].

Clinical Manifestations of axSpA

axSpA Clinical Manifestations

axSpA Clinical Manifestations¹⁻⁶

- axSpA refers to the inflammation of the axial skeleton^{1-3*}
- Clinical features are similar for AS/r-axSpA and nr-axSpA, but the frequencies of some manifestations vary^{4,5}
- Most common symptoms include inflammatory back pain, stiffness, and fatigue^{1,2}





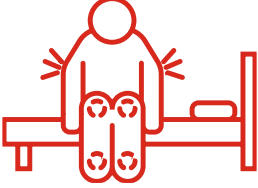


*Vertebral column, ribs, sternum, and skull.^{1,7}

AS=Ankylosing Spondylitis; axSpA=Axial Spondyloarthritis; nr-axSpA=Nonradiographic Axial Spondyloarthritis; r-axSpA=Radiographic Axial Spondyloarthritis; SIJ=Sacroiliac Joint.

1. Taurog JD, et al. *N Engl J Med*. 2016;374(26):2563-2574. 2. Ward MM, et al. *Arthritis Rheumatol*. 2016;68(2):282-298. 3. van der Linden S, et al. *Arthritis Rheum*. 1984;27(4):361-368. 4. de Winter JJ et al. *Arthritis Res Ther*. 2016;18:196. 5. Proft F et al. *Ther Adv Musculoskel Dis*. 2018;10(5-6):129-139. 6. van der Heijde D. *Primer on the Rheumatic Diseases*. 13th ed. New York, NY: Springer; 2008:193,194,196. 7. Caetano AP, et al. *Front Med (Lausanne)*. 2021;8:658538.

Common Symptoms of axSpA

axSpA strikes patients early in life (peak onset between 20 and 30 years of age), leading to longer disease burden over their lifetime.¹

Patients affected	 <p>72%²</p>	 <p>66%⁴</p>	 <p>81%⁵</p>	 <p>89%⁶</p>	 <p>35-90%⁸</p>
Symptoms	Low back pain ^{3a}	Fatigue ^{3,4}	Morning stiffness ^{3,4a}	Mobility restriction ^{3,4,7b}	Sleep difficulty ^{3,4c}
Characteristics	Worsens with rest and improves with exercise. ³	Influenced by multiple factors including chronic inflammation and pain. ⁴	May last a few hours; reflects ongoing inflammation. ⁴	Can permanently be affected due to progressive joint fusion. ⁴	Caused by inflammatory back pain and spinal deformities in more advanced patients. ⁴

^aIn ankylosing spondylitis patients.^{3,4} ^bPatients with Grade II (moderate: Lumbar movement 3-6 cm, thoracic or cervical movement 20°-40°) and Grade III (severe: Lumbar movement <3 cm, thoracic or cervical movement <20°) spinal mobility.⁷ ^cReported as poor sleep quality/too little sleep.⁸

axSpA=Axial Spondyloarthritis.

1. Poddubnyy D, et al. *Rheumatology (Oxford)*. 2022 Aug 3;61(8):3299-3308. 2. Rojas-Vargas M, et al. *Rheumatology (Oxford)*. 2009. 48(4):404-9. 3. Walsh JA, Magrey M. *J Clin Rheumatol*. 2021 Dec 1;27(8):e547-e560. 4. Strand V, Singh JA. *J Clin Rheumatol*. 2017 Oct;23(7):383-391. 5. Şaş S, et al. *J Rheum Dis*. 2023;30(3):176-184. 6. Morton L, et al. *Arthritis Care Res (Hoboken)*. 2022;74(9):1541-1549.

7. Carette S, et al. *Arthritis Rheum*. 1983;26:186-190. 8. Fongen C, et al. *Scand J Rheumatol*. 2024;53(2):130-139.

AS/r-axSpA and nr-axSpA

Similarities

- Similar levels of disease activity (BASDAI, BASFI, QoL)
- Similar prevalence of most peripheral and extra-articular signs
- Where inflammation is present, responses to TNF blockade are similar
- A proportion of patients progress from nr-axSpA to AS, which explains in part the longer disease duration in AS

Differences

- Uveitis is more prevalent in AS/r-axSpA than nr-axSpA patients
- HLA-B27 is more frequent in AS /r-axSpA than in nr-axSpA
- Higher burden of objective inflammation at baseline as measured by MRI or CRP levels in AS /r-axSpA compared to nr-axSpA
- Female gender is more prevalent in nr-axSpA than AS/r-axSpA
- Male gender is more prevalent in AS/r-axSpA

nr-axSpA can be challenging to diagnose due to:

- Lack of radiographic confirmation of disease
- Lower grade of inflammation (on MRI) in women
- Attribution of inflammatory pain to other causes, such as fibromyalgia

Summary



- The IL-17 pathway is key in axSpA pathogenesis¹
- HLA-B27 is the genetic factor known to play an important role in axSpA²
- axSpA refers to inflammation of the axial skeleton and encompasses two subtypes of the same disease such as AS/r-axSpA (presence of radiographic changes of the sacroiliac joints) and nr-axSpA (absence of radiographic changes of the sacroiliac joints) as defined by mNY criteria³
- Clinical features are similar for AS/r-axSpA and nr-axSpA, but the frequencies of some manifestations vary⁴⁻⁶
- Patients with axSpA (AS/r-axSpA and nr-axSpA) carry a similar and high disease burden⁶
- Chronic inflammatory back pain and sacroiliitis are hallmarks of axSpA⁷
- Delay in disease control is associated with worse physical function, increased structural damage, reduced response to treatment, and poor quality of life⁸⁻¹⁰

AS=Ankylosing Spondylitis; axSpA=Axial Spondyloarthritis; IL=Interleukin; mNY=modified New York; nr-axSpA=Nonradiographic Axial Spondyloarthritis; r-axSpA=Radiographic Axial Spondyloarthritis.

1. McGonagle DG, et al. *Ann Rheum Dis*. 2019;78(9):1167-1178. 2. López-Larrea C, et al. *Mol Med Today*. 1998;4(12):540-549. 3. Sieper J, et al. *Ann Rheum Dis*. 2009;68(Suppl 2):ii1-44. 4. Deodhar AA. *Am J Managed Care*. 2019;25(17, suppl):S319-S330. 5. Baraliakos X, et al. *RMD Open*. 2015;1:e000053. 6. Mease PJ, et al. *Arthritis Care Res*. 2018;70(11):1661-1670. 7. Braun J, et al. *Lancet*. 2007;369:1379-1390. 8. Lapane KL, et al. *BMC Fam Pract*. 2021;22(1):251. 9. Zhao SS, et al. *Rheumatology (Oxford)*. 2021;60(4):1620-1628. 10. Yi E, et al. *Rheumatol Ther*. 2020;7(1):65-87.

US Medical Education

For additional resources on
axSpA, scan the code



SCAN HERE

